

FOREIGN BODY NOSE IN CHILDREN: A COMMON PROBLEM WITH SOCIAL ROOTS

*Muhammad Hafeez, **Zakirullah, Inayatullah

*Department of ENT, Khyber Teaching Hospital, Peshawar

**Associate Professor of ENT, Khyber Teaching Hospital, Peshawar

ABSTRACT

Objectives: To determine the patient management factors and patient outcomes in pediatric patients of foreign bodies in nose.

Material and Methods: This descriptive study was performed in ENT Department, Khyber Teaching Hospital, Peshawar from February, 2006 to January, 2007. 257 cases of foreign bodies in nose were included, upto 12 years of age. Personal data, clinical features, investigations, management details and complications were recorded on a pre-designed proforma. In younger non cooperative cases foreign bodies were removed under general anesthesia. While in cooperative children it was removed without anesthesia by using suction, use of forceps and foreign body hook.

Results: Among 257 cases of foreign bodies in nose 48.46% were between 4 to 8 years, with male preponderance i.e. 63%. Unilateral and bilateral presentations were seen in 95% and 5% cases respectively. Most common foreign body types were plastic beads, pearls, pieces of sponge and small round objects. There were 2 cases of alkaline battery lodged in the nose. General anesthesia had high success rate.

Conclusion: Round shape foreign bodies and younger children are associated with poor outcome with removal attempts made under direct visualization. These cases should be referred directly to otolaryngologists for removal under general anesthesia. Moreover the problem is common in children indicating poor parenting and social factors as contributory factors.

Key words: Nose, foreign body, pediatric, general anesthesia.

INTRODUCTION

The removal of foreign bodies in children is very common in the otolaryngologists daily routine.¹ Nasal foreign bodies are commonly encountered in emergency departments. Although more frequently seen in the pediatric setting, they can also affect adults, especially those with mental retardation or psychiatric illness.² Children's interests in exploring their bodies make them more prone to lodging foreign bodies in their nasal cavities. In addition, they may also insert foreign bodies to relieve pre-existing nasal mucosal irritation or epistaxis. As benign as nasal foreign body may seem, it harbors the potential for morbidity and even mortality if the object is dislodged into the airway.^{3,4}

Foreign bodies can be classified as either inorganic or organic. Inorganic materials are typically plastic or metal.⁵ Common examples include beads, buttons, stones, paper and small parts from toys. These materials are often asymptomatic and may be discovered incidentally. Organic foreign bodies, including food, rubber, wood, sponge, and metallic batteries, tend to be more irritating to the nasal mucosa and thus may produce earlier symptoms.⁶

The most common locations for nasal foreign bodies to lodge are just anterior to the middle turbinate or below the inferior turbinate.⁷ Unilateral foreign bodies affect the right side about twice as often compared to the left. This may be due to preference of right handed individuals to insert objects in their right nares.⁸

Button batteries inserted into the nose can cause septal perforation. Unsuccessful efforts to remove the foreign body may cause local injury, pain and bleeding, making subsequent attempts at removal more difficult.^{9,10}

This is an important study to categorize nasal foreign bodies characteristics, frequency in different paediatric age groups, management techniques and to analyze patient outcomes based on these factors. This would help to determine the most appropriate management for paediatric patient with foreign body nose when they present to the emergency department or outpatient department.

MATERIALS AND METHODS

This descriptive study was performed in ENT Department Khyber Teaching Hospital, Peshawar over a period of 1 year from February, 2006 to January, 2007.

257 cases of foreign bodies in nose were included, upto 12 years of age.

Personal data, clinical features, investigations, surgical management details and complications were recorded on a pre-designed proforma. Mostly children presented in emergency or in out patient department along with their parents with complaints of foreign body in nose on the same day, or after 2-3 days, some older than 2-3 weeks. The various methods used for removal of foreign bodies were direct visualization and removal with forceps. Foreign body hook and use of suction. Those children who were not cooperative, or failure of foreign body removal due to deep impaction, or had previous unsuccessful attempts were prepared for removal under general anesthesia.

RESULTS

In our case series the most common paediatric age group involved was 4-8 years (48.46%) as shown in Table 1. The sex distribution was 162 males and 95 females. The most common foreign body type was plastic beads, pearls while other type were sponge piece and paper piece, stones, vegetable seeds, rubber piece and button battery cells.

The emergency department residents had encountered number of complications for removal of foreign bodies without general anesthesia which were bleeding, failure of foreign body removal, deeper displacement and pain.

Table 1: Age Distribution (N=257)

Age group	Number of %	%	Male	Female
1-4 years	85	33.07%	54	31
4-8 years	125	48.46%	72	53
8-12 years	47	18.46%	36	11

Table 2: Type of Foreign Bodies (N=257)

Types of foreign body	Number	%age
Beads or pearls	137	53.3%
Paper	45	17.5%
Sponge piece	35	13.6%
Rubber piece	18	7%
Stones	12	4.6%
Seeds	5	1.94%
Button battery	5	1.94%

Figure 2 shows foreign bodies removed without general anesthesia were 20.7% from 1 to 4 years, 49.9% under 4 to 8 years and 69.8% under 8-12 years of age groups, while under general anesthesia 96.6% from 1-4 years, 84.7% 4-8 years, 55.7% 8-12 years.

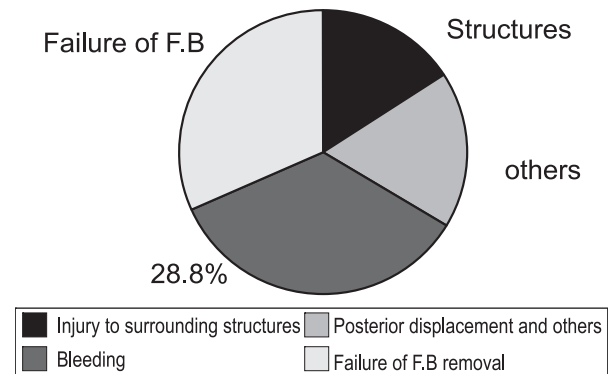


Fig. 1

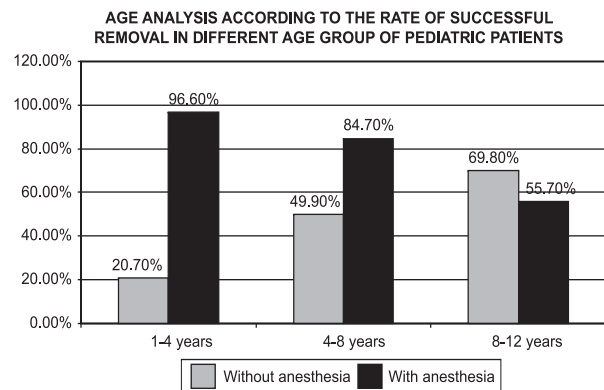


Fig. 2

DISCUSSION

Despite the high frequency of foreign body insertion into the nose, there are very few studies on this problem in literature.¹⁻¹⁰ Success in removing a foreign body nose depends on a number of factors including the size, shape and texture of the foreign body, time duration of F.B, the cooperation of patient at the time of removal, the ability to visualize the F.B and surrounding structure, trauma to the nasal cavity due to insertion or attempted removals of the F.B, the equipment available for removal and skill of the doctor attempting the removal.²

In our study the most common age group was 4 to 8 years. 48.46%. Which was comparable to a study done in Singapore 43.3%.¹¹ While in contrast study done in Lahore showed 71%² in same age group. In our case series foreign bodies were found in males 63.84% and females 36.15%, which is comparable to study done in America in which males 52% and female 48%.

In our case series most common foreign body type were plastic beads and pearls. They were 53.3% while

other type were paper piece 17.5%, sponge piece 13.6%, rubber piece 7%, stones 4.6%, seeds 1.94% and button batteries 1.94%.

We observed that children under 4 years showed lower success rate for foreign body removal without anesthesia (20.7%) than with general anesthesia (96.6%). Patients in this age group have smaller nasal cavities, tends to be some what less cooperative, potentially making FB removal more technically challenging. In the study of Stacey I. shulze, over 95% of patients requiring FB removal under general anesthesia were under 4 years of age.

Alkaline button batteries cause extensive liquefaction necrosis of surrounding tissues by leaking alkaline electrolytes solution causing septal perforation. In our series we had 2 cases of Alkaline button battery septal perforation.¹²

Removal techniques varied in emergency, primarily use is direct visualization with proper instrument for foreign body removal along with use of suction. According to our study spherical foreign bodies demonstrated the largest difference in success rates between direct visualization and removal under general anesthesia, with direct visualization in non cooperative patients having a much lower success rates which was also discussed in davies and Bengner study.¹⁰

We observed that spherical Foreign bodies were associated with highest complication rate due to multiple attempts. In contrast, soft paper or plastic foreign bodies had high success rates of removal under direct visualization. The difference in outcome between these two foreign body classes is likely to be due to the difference in foreign body shape and texture. Spherical foreign bodies are difficult to grasp with nasal forcep, where as paper tissue may offer free edge to grasp easily. Those foreign bodies which did not completely occlude the nasal cavity may be removed by right angle hook but are associated with number of complications.

Outcome of foreign body removal without anesthesia in our study were bleeding 28.8%, failure of foreign body removal 26.4%, injury to surrounding structures 13.2%, posterior displacement 14.9%.

Objects in the nose can cause damage to the nasal cavity and surrounding structures. They can produce local inflammation, which may result in a pressure necrosis. This in turn, can cause mucosal ulceration and erode into blood vessels producing epistaxis. The swelling can cause obstruction to sinus drainage and lead to secondary sinusitis. Organic foreign bodies tend to swell and are usually more symptomatic than inorganic foreign bodies.

Finally impacted and unrecognized foreign bodies can in time become coated with calcium, magnesium, phosphate or carbonate and become a rhinolith.

Rhinoliths can remain undetected for years and only upon growth do they produce symptoms that lead to their discovery. Nasal Foreign bodies often fail to be recognized for large periods of time because they usually produce fewer symptoms and are more difficult to visualize.

There are social implications of this study too which highlights the fact that the condition is common in children because they are not properly taken care of, by their guardians. Large families may be a contributory factor. Therefore parents need to realize that they need to be careful of the small children who are more prone to this condition and careful parenting can significantly reduce this problem

CONCLUSION

Foreign body nose in pediatric patients are commonly encountered in emergency department. In general, nasal foreign bodies can be safely removed by emergency department physician. However the goal of management should be to minimize complications which often occurs from repeated attempts of removal. In may situation direct visualization without anesthesia will allow for successful removal of foreign body, but in cases shown to have low chances of successful removal and high risk of complication, removal of foreign body under general anesthesia should be first line of treatment.

ACKNOWLEDGMENT

Special appreciation is expressed to Mr. Gohar Said (Composing Center) Near KTH, Peshawar for his help in typing and giving a final shape to this article.

REFERENCES

1. Francois M, Hamrioui R, Narcy P. Nasal foreign bodies in children. *Eur Arch Otorhinolaryngol.* 1998; 255 (3): 132-4.
2. Botma M, Bader R, Kubba H. 'A parent's Kiss': evaluating an unusual method for removing nasal foreign bodies in children. *J Laryngol Otol.* 2000; 114 (8): 598-600.
3. Mackle T, Conlon B. Foreign bodies of nose and ears in children. Should these be managed in accident and emergency setting? *Internal Jour Pediatric Otolaryngol* 2006; 70: 425-8.
4. SK Hon, TM Izam, CB Koay, A razi. A prospective evaluation of foreign bodies presenting to the Ear, Nose and Throat clinic, Hospital Kuala Lumpur, *Med. J. Malaysia* 2001; 463-70.
5. A NGO, Kc Ng, TP Sim. Otolaryngneal foreign bodies in children presenting to emergency department. *Singapore Med J* 2005; 172-8.
6. Backlin SA. Positive pressure technique for nasal foreign body removal in children. *Ann Emerg Med.* 1995; 25 (4): 554-5.
7. Baluyot ST, Foreign bodies in the nasal cavity. In:

Paparella MM, Shumrick DA, eds. Otolaryngology. Vol 3. 2nd ed Philadelphia, PA: W.B Saunders, 1980; 2009-2016.

8. Chan TC, Ufberg J, Harrigan RA, et al. Nasal foreign body removal. J Emerg Med. 2004; 26 (4): 441-5.

9. S..K. Das, Aetiological evaluation of foreign bodies in the ear and nose, J. Laryngol. Otol. 98 (1984); 989-991.

10. Davis P, Bengen J. Foreign bodies in the nose and ear: a review of technique for removal in emergency department. J Accid Emerg Med 2000; 17: 91-4.

11. M.C. F. Tong. S.Y. Ying, C.A vanHasselt, Nasal foreign bodies in children, Int. J. Pediatr. Otorhinolaryngol. 35 (1996) 207-211.

12. Hong D, Chu YF, Tong KM, et al. Button battery as a foreign body in the nasal cavities. Int J Pediatr Otorhinolaryngol. 1987; 14 (1): 15-19.